

Brief Communication

Electrical stimulation of a small brain area reversibly disrupts consciousness

Mohamad Z. Koubeissi ^{a,*}, Fabrice Bartolomei ^{b,c}, Abdelrahman Beltagy ^d, Fabienne Picard ^e^a Department of Neurology, George Washington University, 2150 Pennsylvania Avenue, Suite 9-405, Washington, DC 20037, USA^b INSERM, U751, Laboratoire de Neurophysiologie et Neuropsychologie, Marseille F-13005, France; Aix Marseille University, Faculté de Médecine, Marseille F-13005, France^c CHU Timone, Service de Neurophysiologie Clinique, Assistance Publique des Hôpitaux de Marseille, Marseille F-13005, France^d Epilepsy center, Neurological Institute, University hospitals, Case Western Reserve University, 11100 Euclid Ave. Cleveland, OH 44106, USA^e Department of Neurology, University Hospital and Medical School of Geneva, 4 rue Gabrielle-Perret-Gentil, 1211 Geneva 14, Switzerland

ARTICLE INFO

Article history:

Received 12 February 2014

Revised 9 May 2014

Accepted 27 May 2014

Available online xxxx

Keywords:

Consciousness

Electrical stimulation

Epilepsy

Insula

Claustrum

ABSTRACT

The neural mechanisms that underlie consciousness are not fully understood. We describe a region in the human brain where electrical stimulation reproducibly disrupted consciousness. A 54-year-old woman with intractable epilepsy underwent depth electrode implantation and electrical stimulation mapping. The electrode whose stimulation disrupted consciousness was between the left claustrum and anterior-dorsal insula. Stimulation of electrodes within 5 mm did not affect consciousness. We studied the interdependencies among depth recording signals as a function of time by nonlinear regression analysis (h^2 coefficient) during stimulations that altered consciousness and stimulations of the same electrode at lower current intensities that were asymptomatic. Stimulation of the claustral electrode reproducibly resulted in a complete arrest of volitional behavior, unresponsiveness, and amnesia without negative motor symptoms or mere aphasia. The disruption of consciousness did not outlast the stimulation and occurred without any epileptiform discharges. We found a significant increase in correlation for interactions affecting medial parietal and posterior frontal channels during stimulations that disrupted consciousness compared with those that did not. Our findings suggest that the left claustrum/anterior insula is an important part of a network that subserves consciousness and that disruption of consciousness is related to increased EEG signal synchrony within frontal–parietal networks.

© 2014 Elsevier Inc. All rights reserved.

1. Introduction

Although the neural mechanisms that underlie consciousness are unclear, clinicians tend to separate it into wakefulness and awareness. Wakefulness depends upon the functional integrity of subcortical arousal systems in the brainstem and thalamus [1]. Awareness refers to the content of experience as regards both the environment and the self and is thus defined as the capacity to respond to external stimuli while having an internal and qualitative experience of existence. The external awareness network seems to encompass bilateral dorsolateral prefrontal cortices and lateral posterior parietal cortices, whereas the internal awareness network seems to include the midline posterior cingulate cortex/precuneus and anterior cingulate/medial prefrontal cortices [2]. A complete disruption of consciousness during the waking state, involving the perception of both external and internal stimuli, is often experienced by patients with epilepsy, regardless of the area of seizure origin in the brain. Indeed, disruption of consciousness is one of the

most disabling manifestations of epileptic seizures that affects quality of life [3]. However, the precise structures and pathophysiological mechanisms involved in impairment of consciousness in epileptic seizures remain a matter of debate [4–6].

Common brain regions are thought to be involved in all seizures that interfere with consciousness, regardless of their onset zones and variations in semiology. These regions include the frontoparietal association cortex and the subcortical arousal system in the brainstem and thalamus [6]. One hypothesis suggests that alteration of consciousness in partial seizures results from abnormal synchronization of cortical activity between distant brain regions [4] that overloads the structures involved in consciousness processing, affecting their ability to handle incoming information [5,7]. In this report, a finding from the electrical stimulation of the brain during presurgical evaluation of intractable epilepsy in a patient provided direct evidence that a small brain region that encompasses the anterior-dorsal insula and the neighboring claustrum (Fig. 1) is a key component of the network supporting both external awareness and internal awareness. No similar response to electrical stimulation of any other brain region has ever been reported, despite almost a century of experience in electrical cortical stimulation [8].

* Corresponding author. Tel.: +1 202 741 2533; fax: +1 202 677 6206.
E-mail address: mkoubeissi@mfa.gwu.edu (M.Z. Koubeissi).

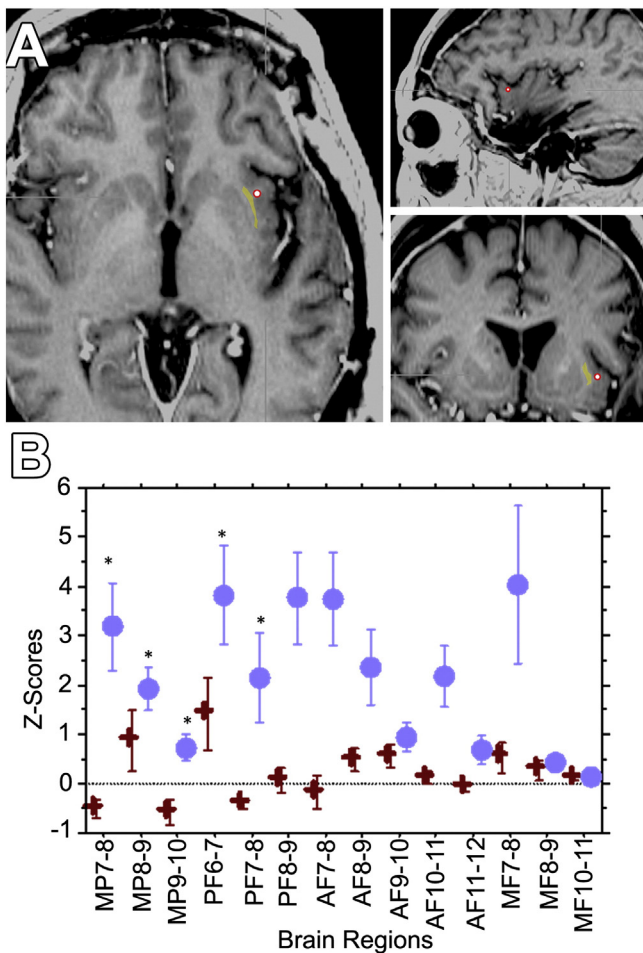


Fig. 1. A. Location of the AI4 contact (red circle) whose stimulation elicited impairment of consciousness. The location, shown in three different planes, was determined by superimposition of preoperative brain MRI with postoperative volumetric head CT scan according to anatomic fiducials. The claustrum is highlighted in yellow to show its proximity to the stimulating contact. B. Variations of h^2 coefficients estimated by Z-scores relative to the prestimulation period in 15 selected bipolar channels. Blue circle: Two stimulations of AI4, chosen at random from among ones that cause disruption of consciousness and red cross: 2 stimulations chosen at random stimulations of AI4 that did not interfere with consciousness at lower current intensities. The significant variations are mainly observed in medial parietal (MP) channels and posterior frontal (PF) channels. AF, anterior frontal; MF, medial frontal.

2. Methods

2.1. Subject and clinical setting

A 54-year-old woman with a history of intractable epilepsy, characterized by olfactory auras followed by disruption of consciousness and occasional secondarily generalized seizures, underwent left hippocampotomy sparing the amygdala. The patient remained seizure-free for four years before habitual seizures recurred, necessitating depth electrode evaluation. Since the seizures were consistent with a mesial temporal origin, intraparenchymal electrodes were implanted in the anterior hippocampal remnant and in structures that have known connectivity with the mesial temporal structures: the left amygdala, posterior cingulate gyrus, medial and lateral frontal regions, and anterior and posterior insula, in addition to two electrodes in the posterior quadrant sampling the temporoparietal and temporooccipital regions. Bilateral scalp electrodes were also placed. No subdural electrodes were placed. One depth electrode that sampled the left anterior insula included a contact, AI4, in the extreme capsule and in close proximity to the anterior insular cortex and the claustrum (Fig. 1).

2.2. Cortical synchrony assessment

We studied interdependencies between signals from different brain regions by using nonlinear regression analysis during stimulations that interfered with consciousness and those that did not. For this, our aim was to assess changes in synchronization between remote brain regions, particularly frontoparietal networks, during AI4 stimulations that induced disruption of consciousness (14 mA) and compare them with control stimulations of the same electrode at lower current intensities (2–12 mA) that did not interfere with consciousness. Interdependencies between bipolar signals recorded from 15 contacts that sampled evenly most implanted regions, including frontoparietal areas, were estimated as a function of time by using nonlinear regression analysis. Details of the method are described elsewhere [4]. Nonlinear regression analysis provides a parameter, referred to as the nonlinear correlation coefficient h^2 , whose values lie in the range [0, 1]. Low values of h^2 denote independence of signals, whereas high values of h^2 denote signal dependence by signifying that one signal is related via a (likely nonlinear) transformation to another. The analysis was performed over a sliding window of two-second duration by steps of 0.25 s. The h^2 values were averaged over each period of interest defined for each of the 105 considered pairs of signals and for two AI4 stimulations that interfered with consciousness and two control stimulations (at 6 mA) of the same electrode that did not interfere with consciousness.

To assess the functional connectivity between parietofrontal cortices, we chose 3 bipolar channels from the medial parietal cortex, including the precuneus; 4 from lateral frontal region; 5 from anterior frontal region; and 3 from medial frontal region. The h^2 values were computed on broadband signals (0.5–90 Hz), providing a global estimation of nonlinear interdependencies. Two periods were considered for analysis: a 10-second background (BG) period chosen just before the start of the stimulation and an 8-second period covering the stimulation period (SP). The h^2 values were averaged over BG and SP periods. Changes in h^2 values obtained during the SP period relative to the BG period were evaluated by calculating the variation of h^2 values in terms of Z-scores [$Z_{h^2} = ((\text{mean } h^2(\text{SP}) - \text{mean } h^2(\text{BG})) / \text{SD}(\text{BG}))$]. These values were then averaged over time in order to get an estimate (mean \pm SD) of the degree of coupling between selected channels. For each selected channel, we calculated the h^2 values between all possible pairs. The differences in values obtained from positive (disrupting consciousness) versus negative (asymptomatic) stimulations of AI4 were compared using a Mann–Whitney test and corrected for multiple comparison using Bonferroni correction.

3. Results

The patient's seizures originated from the left amygdala. Electrical stimulation of medial frontal electrodes was done initially, and no symptoms were elicited at currents reaching 18 mA. Then, one of these “clinically silent” electrodes was used as a reference for electrical stimulation of all remaining contacts. Stimulating AI4 using biphasic waves at 14 mA (50 Hz, 0.2-ms pulse width, 3- to 10-second train duration), but not at lower intensities, resulted in immediate impairment of consciousness, in 10 out of 10 times, with arrest of reading, onset of blank staring, unresponsiveness to auditory or visual commands, and slowing of spontaneous respiratory movements. The patient returned to baseline as soon as the stimulation stopped with no recollection of the events during the stimulation period. Occasionally, the induced impairment of consciousness was associated with scanty, perseverative, and incomprehensible verbal output consisting of one or two syllables, with a confused look on the face. No abnormal discharges outlasting the stimulation were seen on depth electrode recordings or scalp electroencephalogram (EEG). Specifically, the raw EEG in frontoparietal regions did not show any deviation from baseline during the stimulation step that elicited disruption of consciousness as well as during those that did not. Stimulation of the adjacent electrode contacts did not elicit the same phenomena.

The symptoms elicited by AI4 stimulation could not be attributed to negative motor phenomena because the patient was able to continue repetitive movements with the tongue and hands during stimulation if initiated before the stimulus train. Such movements would continue decrescendo for up to 4 s through stimulation before pausing. Also, the finding could not be attributed to aphasia because of maintained ability to repeat a word if the task was initiated before stimulation. The repetition would continue for approximately 2 s during the beginning of stimulation, although with some dysarthria, before pausing completely. The patient was unable to recall any words given to her during stimulation. Stimulations repeated on the following day showed consistent findings.

In the study of interdependencies between signals from different brain regions by using nonlinear regression analysis during stimulations that resulted or not in disruption of consciousness, we found that changes from the BG period were dramatically different during stimulations that resulted in disruption of consciousness when compared with “control” stimulations. Fig. 1 shows the mean Z-score values (and SD) obtained for the interactions calculated for each selected bipolar channel. Overall increased values were found when comparing control stimulations and positive (inducing disruption of consciousness) AI4 stimulations. Finally, a significant increase in correlation (when comparing control and positive stimulation Z-score values) was found for interactions affecting medial parietal and posterior frontal channels.

4. Discussion

Despite decades of electrocortical stimulation mapping as a routine procedure in patients with epilepsy, to our knowledge, the disruption of consciousness that we herein describe has never been precipitated by electrical stimulation of any other site in the human brain, including the hippocampus, amygdala, cingulate cortex, or various areas of the insula and other neocortical regions [8–10]. The immediate impairment of consciousness due to direct stimulation of the left anterior-dorsal insula/claustum region, without any afterdischarges, suggests that this effect arises from functional interruption of the anterior insula, the claustum, or both. The anterior-dorsal insula seems to play a role in self-awareness and integrates emotional and cognitive inputs, setting the context for actions [11]. However, there have been no previous reports that stimulations of different parts of the insula result in an alteration of consciousness [9]. AI4 was the closest contact to the claustum, and the stimulation of neighboring contacts that were within 2.7 mm did not elicit such phenomena. Thus, the claustum – a region in which the effects of electrical stimulations have never been reported to our knowledge in humans – could be a key component of the network supporting “conscious awareness” during wakefulness. The claustum could constitute a common gate to the “external” and “internal” awareness networks. This could explain why the electrical stimulation of the claustum, and the resulting alteration of its normal function, would cause an impairment of consciousness, including an absence of recollection of the external events and of internal/interoceptive experience. This may support previous hypotheses that the claustum is related to the processes that give rise to integrated conscious percepts [12].

We found that stimulations that caused disruption of consciousness were associated with increased correlations in regions participating in the global workspace of consciousness and could block transiently its functioning [5]. This has been found to be the case in temporal lobe [4] and parietal [13] seizures that cause disruption of consciousness. Excessive synchronization between the thalamus and parietal cortex was associated with disruption of consciousness that accompanies temporal lobe seizures, rather than disruption of temporal lobe function alone [4]. Our finding further suggests that the claustum appears to be a component of the neural correlates of consciousness mediating increased synchronization between various cortical regions. Another hypothesis regarding the alteration of consciousness that accompanies seizures, the “network inhibition hypothesis”, suggests that propagation of ictal discharges from the mesial temporal structures to the brainstem and

diencephalon results in inhibition of the subcortical arousal system, which results in widespread depression of cortical activity [6]. Because of a widespread connectivity with neocortical areas, it is possible that the claustum participates in the widespread cortical depression.

In one study, electrical stimulation of the claustum resulted in the alteration of awareness in nonanesthetized cats, causing the cats to crouch and close their eyes and become unresponsive to external stimulation [14]. Indeed, the claustum may play a role in computational processes that involve different brain areas by coordinating distant synchronized activities and controlling voluntary behavior. Such coordination by the claustum – likened by Crick and Koch to the conductor of an orchestra [12] – would make it an important part of the neural correlates of consciousness. Interestingly, a recent EEG/fMRI study in patients with different focal epilepsies found a common brain region in all patients that showed increased hemodynamic responses in relation to interictal epileptiform discharges, regardless of the localization of interictal and ictal activity [15]. This region was close to the frontal piriform cortex, and its Talairach coordinates suggest that it corresponds to the claustum. As most of the patients suffered from complex partial seizures, this region could be part of an anatomic circuit acting as a critical modulator of seizure propagation and could possibly be responsible for the dyscognitive component of focal seizures.

The electric current that elicited disruption of consciousness in our patient was rather high, 14 mA. Thus, one may entertain the possibility that this current might have resulted in afterdischarges or seizures in brain regions that were not implanted with depth electrodes, without necessarily appearing on the scalp electrodes either. While we cannot totally rule out this possibility, the fact that the patient’s disruption of consciousness immediately reversed upon termination of the stimulation train suggests that it was directly induced by the stimulation of the insula/claustum region. This is in contrast to or seizure discharges which typically outlast the electrical stimulation. Another limitation of this report is the lack of right hemispheric stimulation. Whether stimulating the left claustum interferes with only left hemispheric versus bilateral networks remains to be established.

In conclusion, our observation indicates that loss of consciousness can be artificially induced by electrical stimulation of a specific and limited brain region. This is the first report of a loss of consciousness induced by the stimulation of a limited area of the brain. Further studies in other patients with depth electrodes exploring the insula/claustum could help to confirm our finding. A therapeutic implication could be deep brain stimulation of the region at lower current intensities or low frequencies in order to treat the disruption of consciousness occurring in epilepsy.

Conflict of interest statement

The authors report no conflict of interest related to this work.

References

- [1] Tononi G, Koch C. The neural correlates of consciousness: an update. *Ann N Y Acad Sci* 2008;1124:239–61.
- [2] Demertzi A, Soddu A, Laureys S. Consciousness supporting networks. *Curr Opin Neurobiol* 2013;23(2):239–44.
- [3] Blumenfeld H. Epilepsy and the consciousness system: transient vegetative state? *Neurol Clin* 2011;29(4):801–23.
- [4] Arthuis M, et al. Impaired consciousness during temporal lobe seizures is related to increased long-distance cortical-subcortical synchronization. *Brain* 2009;132(Pt 8):2091–101.
- [5] Bartolomei F, Naccache L. The global workspace (GW) theory of consciousness and epilepsy. *Behav Neurol* 2011;24(1):67–74.
- [6] Blumenfeld H. Impaired consciousness in epilepsy. *Lancet Neurol* 2012;11(9):814–26.
- [7] Bartolomei F, et al. Pre-ictal synchronicity in limbic networks of mesial temporal lobe epilepsy. *Epilepsy Res* 2004;61(1–3):89–104.
- [8] Selimbeyoglu A, Parvizi J. Electrical stimulation of the human brain: perceptual and behavioral phenomena reported in the old and new literature. *Front Hum Neurosci* 2010;4:46.
- [9] Isnard J, et al. Clinical manifestations of insular lobe seizures: a stereo-electroencephalographic study. *Epilepsia* 2004;45(9):1079–90.

- [10] Penfield W. Some mechanisms of consciousness discovered during electrical stimulation of the brain. *Proc Natl Acad Sci U S A* 1958;44(2):51–66.
- [11] Kurth F, et al. A link between the systems: functional differentiation and integration within the human insula revealed by meta-analysis. *Brain Struct Funct* 2010;214(5–6):519–34.
- [12] Crick FC, Koch C. What is the function of the claustrum? *Philos Trans R Soc Lond B Biol Sci* 2005;360(1458):1271–9.
- [13] Lambert J, et al. Alteration of global workspace during loss of consciousness: a study of parietal seizures. *Epilepsia* 2012;53(12):2104–10.
- [14] Gabor AJ, Peele TL. Alterations of behavior following stimulation of the claustrum of the cat. *Electroencephalogr Clin Neurophysiol* 1964;17:513–9.
- [15] Laufs H, et al. Converging PET and fMRI evidence for a common area involved in human focal epilepsies. *Neurology* 2011;77(9):904–10.